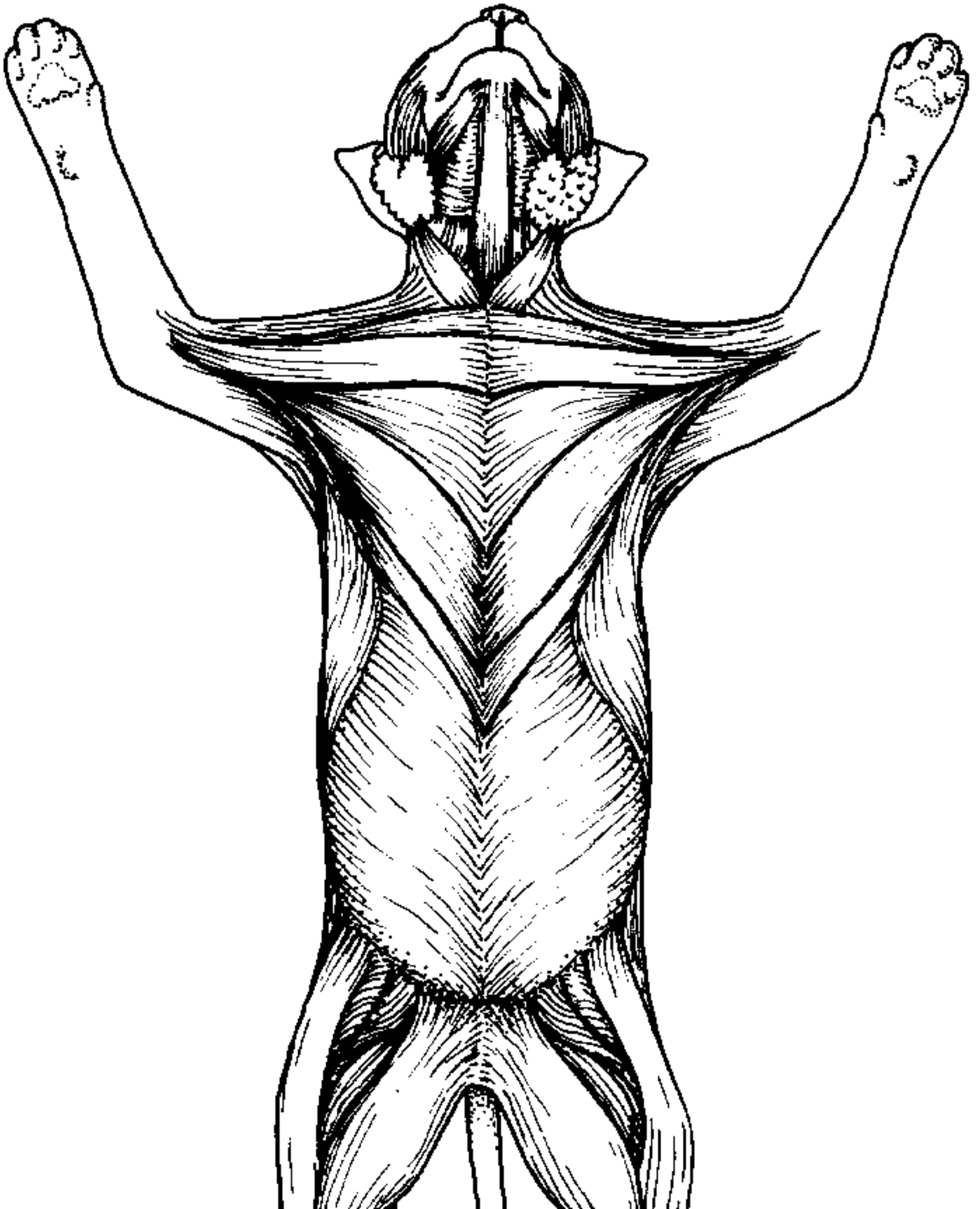
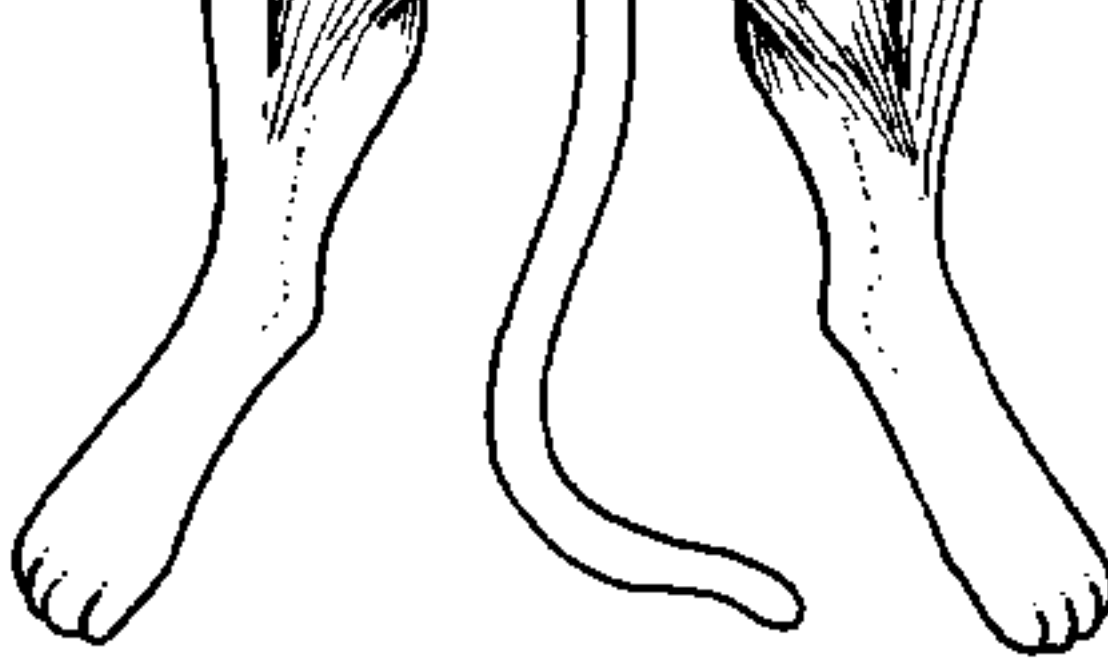

Cat Muscles Ventral Region

Name: _____

Use resources, such as laboratory manuals to locate and color each of the superficial muscles of the cat's ventral region.





Guy/96

Livingstone © BIODIDAC

- | | | |
|--|--|---|
| 1. Sartorius <input type="checkbox"/> | 5. Xiphohumeralis <input type="checkbox"/> | 8. Pectoantebrachialis <input type="checkbox"/> |
| 2. Gracilis <input type="checkbox"/> | 6. Pectoralis minor <input type="checkbox"/> | 9. Sternomastoid <input type="checkbox"/> |
| 3. External Oblique <input type="checkbox"/> | 7. Pectoralis major <input type="checkbox"/> | 10. Clavobrachialis <input type="checkbox"/> |
| 4. Latissimus Dorsi (can be seen partially) <input type="checkbox"/> | | |

Image courtesy of [biodidac](#))

|| Downloadable [.doc file](#) | [Cat Coloring Sample \(key\)](#)